

DOI: <https://doi.org/10.26694/jcshuufpi.v5i1.2278>

## RADICULAR CYST ASSOCIATED WITH A PRIMARY MOLAR: A RARE CASE REPORT AND FOLLOW-UP

CISTO RADICULAR ASSOCIADO A UM MOLAR PRIMÁRIO: UM RELATO E ACOMPANHAMENTO DE UM CASO RARO

*Lúcia de Fátima Almeida de Deus Moura<sup>1</sup>, Marina de Deus Moura Lima<sup>2</sup>, Joyce Samandra Silva Moura<sup>3</sup>, Natália Gonçalves Nogueira<sup>4</sup>, Marcus Victor Vaz Soares Castro<sup>5</sup>, Rafael de Deus Moura<sup>6</sup>*

<sup>1</sup>Professor in the Graduate Program in Dentistry, Federal University of Piauí, Teresina –PI, Brazil. E-mail: [mouraiso@uol.com.br](mailto:mouraiso@uol.com.br) Orcid: <https://orcid.org/0000-0002-4112-1533>

<sup>2</sup>Professor in the Graduate Program in Dentistry, Federal University of Piauí, Teresina –PI, Brazil. E-mail: [mdmlima@gmail.com](mailto:mdmlima@gmail.com) Orcid: <https://orcid.org/0000-0002-7641-6331>

<sup>3</sup>Graduate Program in Dentistry's Student, Federal University of Piauí, Teresina –PI, Brazil. E-mail: [joycesamandrasilva@gmail.com](mailto:joycesamandrasilva@gmail.com)

<sup>4</sup>Graduate Program in Dentistry's Student, Federal University of Piauí, Teresina –PI, Brazil. E-mail: [natalianogueira43@gmail.com](mailto:natalianogueira43@gmail.com) Orcid: <https://orcid.org/0000-0003-0703-5786>

<sup>5</sup>Graduate Program in Dentistry's Student, Federal University of Piauí, Teresina –PI, Brazil. E-mail: [m.vvazod@gmail.com](mailto:m.vvazod@gmail.com) Orcid: <https://orcid.org/0000-0002-5188-1288>

<sup>6</sup>Professor of Pathology, Federal University of Piauí, Teresina –PI, Brazil. E-mail: [dedeusmoura@gmail.com](mailto:dedeusmoura@gmail.com) Orcid: <https://orcid.org/0000-0002-2260-1179>

### ABSTRACT

**Introduction:** The development of radicular cysts in primary dentition is an unusual occurrence. A relation with pulp treatments has been reported and represent an issue to be considered on treatments follow up. **Case description:** A seven-year-old female child had a necrosed mandibular right second primary molar pulpectomized with zinc oxide and eugenol paste. At the nine-month radiographic evaluation, there was an image compatible with a radicular cyst. Dental extraction with enucleation of the cyst was made. Histopathological evaluation confirmed the diagnosis of radicular cyst. At the 18-month, after surgical procedure, the premolar showed crown eruption and radiographic normality. **Conclusion:** Follow up schedule is important to interfere soonely in case of pathological infectious reaction after pulp treatments in primary teeth.

**KEYWORDS:** Radicular cyst. Deciduous. Dental pulp necrosis. Pediatric dentistry. Pulpectomy.

---

## RESUMO

**Introdução:** O desenvolvimento de quistos radiculares na dentição primária é uma ocorrência invulgar. Foi relatada uma relação com os tratamentos de polpa e representa uma questão a ser considerada no seguimento dos tratamentos. **Descrição do caso:** Uma criança de sete anos de idade, do sexo feminino, tinha um segundo molar primário necrosado da mandíbula direita pulpectomizado com óxido de zinco e pasta de eugenol. Na avaliação radiográfica de nove meses, houve uma imagem compatível com um quisto radicular. Foi feita uma extracção dentária com enucleação do cisto. A avaliação histopatológica confirmou o diagnóstico de cisto radicular. Aos 18 meses, após procedimento cirúrgico, o pré-molar mostrou erupção da coroa e normalidade radiográfica. **Conclusão:** O calendário de seguimento é importante para interferir em breve em caso de reacção infecciosa patológica após tratamentos de polpa em dentes primários.

**DESCRITORES:** Cisto Radicular. Dente Decíduo. Necrose da polpa dentária.

---

### Como citar este artigo (Vancouver):

Moura LFAD, Lima MDM, Moura JSS, Nogueira NG, Castro MVVS, Moura RD. Radicular cyst associated with a primary molar: a rare case report and follow-up. J. Ciênc. Saúde [internet]. 2022 [acesso em: dia mês abreviado ano]; JCS HU-UFPI. Jan. - Abr. 2022; 5(1):7-12. Disponível em: DOI: <https://doi.org/10.26694/jcshuufpi.v5i1.2278>



Esta obra está licenciada sob uma Licença *Creative Commons* [Atribuição 4.0 Internacional](https://creativecommons.org/licenses/by/4.0/).

## INTRODUCTION

---

Radicular cysts are lesions of odontogenic origin that are derived from inflammatory activation of the epithelial root sheath residues of cell rests of Malassez in the periodontal ligament<sup>(1)</sup>. Their etiology is related to pulp infections<sup>(1)</sup>, nevertheless there have been reports of their association with endodontic treatment and the rapid growth of radicular cysts<sup>(1-2)</sup>. In general, they are asymptomatic, therefore, they are diagnosed in radiographs<sup>(3)</sup>. Histopathological examination is required<sup>(4)</sup> to confirm the diagnosis. Treatment options include removal of the primary tooth affected, and cystic enucleation or marsupialization<sup>(1)</sup>.

In primary dentition, the prevalence of radicular cysts varies from 0.5 to 3.3%<sup>(5)</sup>, and they occur more frequently in males and in mandibular molars<sup>(6)</sup>. Persistent periapical lesions in primary teeth may lead to bone resorption, delayed eruption, incorrect positioning of the permanent successor teeth<sup>(3)</sup> or developmental enamel defects<sup>(7)</sup>.

The objective of this article was to report the clinical case and the follow-up of a child with a radicular cyst associated with a primary molar with pulp necrosis, in which endodontic treatment was performed.

## CASE REPORT

---

The patient, a seven-year-old female patient sought care at the Pediatric Dentistry Clinic complaining of pain in the primary mandibular right second molar that had extensive carious lesions, with sinus tract/swelling and mobility (Figure 1-a). The radiographic image demonstrated a radiolucent area in the furcation region and [regions of] internal and external pathological resorptions (Figure 1-b). The treatment option was pulpectomy, using zinc oxide paste and eugenol and restoration with a stainless-steel crown. The parents/guardians of the child signed a term of free and informed consent, and the child a term of informed consent.

The procedure was started by blocking the mandibular alveolar nerve with one percent lidocaine

hydrochloride with a vasoconstrictor (DFL, Rio de Janeiro, Brazil); and absolute isolation with a rubber dam. Decayed dentin was removed using dentin excavators and low-rotation spherical drills numbers four and six (Microdont, São Paulo, Brazil). The pulp chamber roof was removed with a high-speed sterile carbide bur number 330 (KG Sorensen, Cotia, Brazil). Root canal debridement and disinfection were performed using a two percent chlorhexidine solution (LT Rioquímica, São José do Rio Preto, Brazil) and K-files (sizes 15 to 25; Dentsply, São Paulo, Brazil). The limit of manual instrumentation was one mm short of the radiographic apex.

The zinc oxide of the ZOE paste was packed into 250mg capsules at Federal University of Piauí Pharmacy School, mixed with 0.1 mL of eugenol (Biodinâmica, Ibiporã, Brazil). The paste was inserted manually with K-files (sizes 15 to 25; Dentsply, São Paulo, Brazil), respecting the limit of one mm short of the radiographic apex. The ZOE paste was physically protected with a thin layer of gutta-percha.

The tooth was restored with high-viscosity glass ionomer cement (Gold Label 9R, GC, Tokyo, Japan). After the removal of the rubber dam, SSC was cemented (Iso-Form, 3M ESPE, Minneapolis, USA) with glass ionomer cement (Ketac Cem Easy Mix, 3M ESPE).

At the six-month evaluation, the tooth exhibited clinical characteristics of normality and the lesion in the furcation region was stable.

At the nine-month evaluation, the patient reported no pain in the tooth or abscess. However, radiographic examination showed an oval radiolucent image circumscribed by a well-defined radiopaque line around the tooth, suggestive of radicular cyst (Figure 1-c). The mandibular right second premolar was shown to have 1/3 of its root formed (Figure 1-c).

The treatment option was extraction of the primary tooth and enucleation of the cystic membrane under local anesthesia. Cystic site was exposed through intraoral approach after extraction of the primary teeth and cystic lining was enucleated and submitted for histopathological examination. Histopathological examination revealed a cystic lesion with squamous epithelial lining and no atypia, showing exocytosis of lymphocytes and capsule of connective tissue

permeated by a chronic inflammatory process compatible with radicular cyst (Figure 2).

At the 9-month reassessment after the surgical procedure, the mandibular right second premolar had erupted (Figure 1-d), and the radiographic examination was normal.

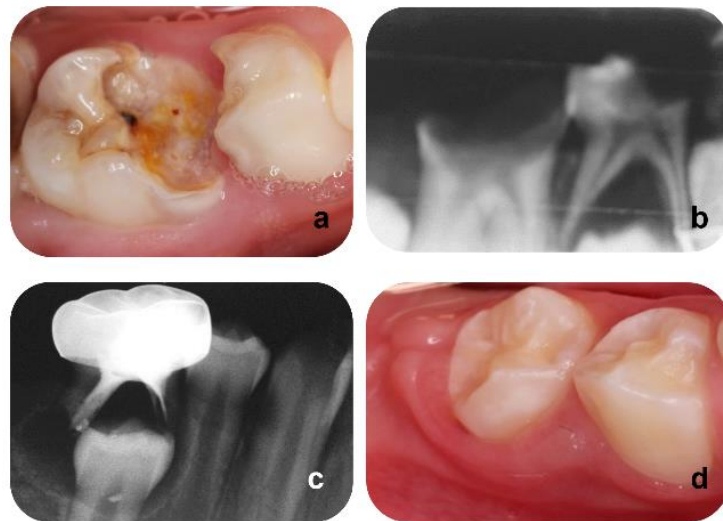


Figure 1: Initial clinical and radiographical evaluation- a and b. At the 9 month-evaluation, an oval radiolucent image involving the tooth was observed- c. Succedaneous tooth erupted presented no alterations - d. Pediatric Dentistry Clinic/ PI- Brazil 2019.

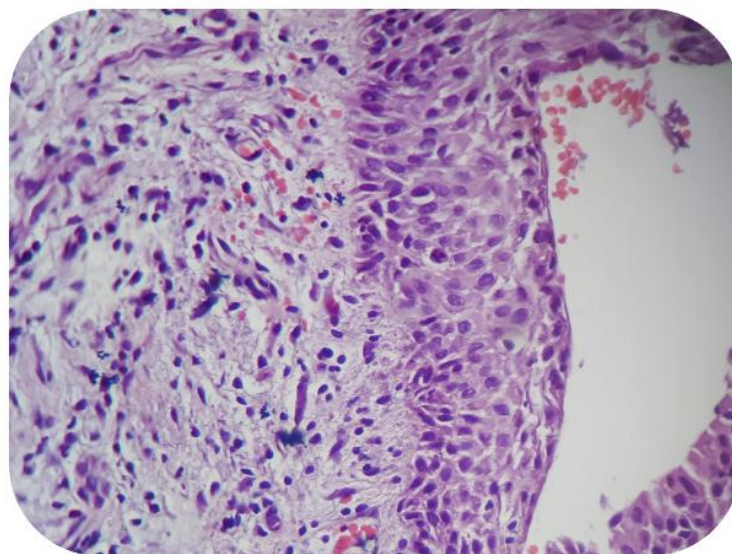


Figure 2: Histopathological examination showing exocytosis of lymphocytes and capsule of connective tissue permeated by a chronic inflammatory process. Pediatric Dentistry Clinic/ PI- Brazil 2019.

## DISCUSSION

---

Radicular cysts rarely occur in primary dentition<sup>(3, 6)</sup> and several factors may contribute to this low prevalence, such as the shorter biological cycle of primary teeth<sup>(2)</sup>, difficulties with making a radiographic diagnosis<sup>(8)</sup> and undervaluation of injuries<sup>(2-3)</sup>. Pulp and periapical infections in primary teeth tend to drain more easily due to the formation of sinus tract/swelling formation, thus minimizing signs and symptoms when compared with permanent teeth<sup>(2)</sup>.

The mean age of children with root cysts is eight years<sup>(6)</sup>, coinciding with that of the child described in this case report. Mandibular primary molars are the teeth most affected by this pathology, as these teeth more frequently have caries lesions<sup>(3)</sup> and higher prevalence of enamel hypomineralization that is associated with dental caries<sup>(9)</sup>.

Several of the radicular cysts reported in literature have been associated with pulp therapies<sup>(1-2, 6, 10)</sup>, but it is not possible to confirm whether the cyst was caused by the pulp necrosis or by the endodontic treatment. Root filling materials based on zinc oxide and eugenol (ZOE)<sup>(10)</sup>, and agents used for pulp therapy such as formocresol<sup>(2)</sup>, have been associated with the growth of radicular cysts. These materials may have antigenic action in synergism with tissue proteins, which could trigger humoral and cell-mediated responses, leading to the development of root cysts<sup>(2, 10)</sup>.

One of the main factors related to the failure of pulp therapies is restoration failures<sup>(11)</sup>. However, in the clinical case presented herein, restoration was performed with stainless steel crowns, which present high clinical and radiographic success rates<sup>(12)</sup>.

The complex morphology of primary molar root canals, associated with irregular resorption and inadequate behavior of children at early age, make it difficult to perform adequate mechanical chemical preparation, with the consequent risk of microorganisms remaining in certain regions<sup>(13)</sup>.

Therefore, dentists must be aware of utmost importance of implementing clinical and radiographic follow-up of primary teeth, after they have been submitted to endodontic treatment, considering the technical difficulties involved in performing these procedures<sup>(14)</sup> and the possibility of continuous antigenic stimulation<sup>(15)</sup>.

## CONCLUSION

---

This case demonstrates that clinical and radiographic follow up after endodontic treatment in primary teeth is important to assess the success of the intervention and make possible interfere soonely in case of pathological infectious reaction.

## REFERENCES

---

1. Truong-Nhu-Ngoc V, Vu-Thai-Lien N, Minh-Hang L, *et al.* Radicular cyst in a primary molar following pulp therapy with gutta percha: A case report and literature review. *J Clin Exp Dent.* 2019; 11(1):85-90. DOI: 10.4317/jced.55309
2. Sevekar S, Subhadra HN, Das V. Radicular cyst associated with primary molar: Surgical intervention and space management. *Indian J Dent Res.* 2018;29(6):836-9. DOI: 10.4103/ijdr.IJDR\_785\_16
3. Talukdar M, Kumar A, Goenka S, Mahajani M, Ambhore MP, Tattu VD. Management of radicular cyst in deciduous molar: A case report. *J Family Med Prim Care.* 2020;9(2):1222-5. DOI: 10.4103/jfmpc.jfmpc\_1147\_19
4. Narsapur SA, Chinnanavar SN, Choudhari SA. Radicular cyst associated with deciduous molar: a report of a case with an unusual radiographic presentation. *Indian J Dent Res.* 2012; 23(4):550-3. DOI: 10.4103/0970-9290.104970
5. Bhaskar SN. Oral surgery--oral pathology conference No. 17, Walter Reed Army Medical Center. Periapical

lesions--types, incidence, and clinical features. *Oral Surg Oral Med Oral Pathol.* 1966;21(5):657-71. DOI: 10.1016/0030-4220(66)90044-2

6. Nagata T, Nomura J, Matsumura Y, *et al.* Radicular cyst in a deciduous tooth: a case report and literature review. *J Dent Child.* 2008; 75(1):80-4. Available in: <https://www.ingentaconnect.com/content/aapd/jodc/2008/00000075/00000001/art00016;jsessionid=22vmp6w7cf58a.x-ic-live-01>

7. Sousa HCS, Lima MDM, Lima CCB, Moura MS, Bandeira AVL, Deus Moura LFA. Prevalence of Enamel Defects in Premolars Whose Predecessors Were Treated with Extractions or Antibiotic Paste. *Oral Health Prev Dent.* 2020;18(1):793-8. DOI: 10.3290/j.ohpd.a45083

8. Khan I, Ansari MI, Mansoori S, Saalim M. "Looks Can be Deceptive" - Radicular Cyst Mimicking a Developmental Origin Cyst. *The Journal of craniofacial surgery*, 32(7), e616–e618. DOI: 10.1097/SCS.00000000000007597

9. Carvalho JC, Silva EF, Gomes RR, Fonseca JA, Mestrinho HD. Impact of Enamel Defects on Early Caries Development in Preschool Children. *Caries Res.* 2011; 45:53–60. DOI: 10.1159/000329388

10. Sandhyarani B, Noorani H, Shivaprakash PK, Dayanand AH. Fate of pulpectomized deciduous teeth: Bilateral odontogenic cyst?. *Contemp Clin Dent.* 2016; 7(2):243-5. DOI: 10.4103/0976-237X.183054

11. Brustolin JP, Mariath AA, Ardenghi TM, Casagrande L. Survival and Factors Associated with Failure of Pulpectomies Performed in Primary Teeth by Dental Students. *Braz Dent J.* 2017; 28(1):121-8. DOI: 10.1590/0103-6440201601009

12. Chisini LA, Collares K, Cademartori MG, *et al.* Restorations in primary teeth: a systematic review on survival and reasons for failures. *Int J Paediatr Dent.* 2018; 28(2):123-39. DOI: 10.1111/ipd.12346

13. De Sousa DL, de Sousa RB, Pinto DN, Neto JJ, de Carvalho CB, de Almeida PC. Antibacterial effects of chemomechanical instrumentation and calcium hydroxide in primary teeth with pulp necrosis. *Pediatr Dent.* 2011; 33(4):307-11. Available in: <https://www.ingentaconnect.com/content/aapd/pd>

14. Ahmed HM. Anatomical challenges, electronic working length determination and current developments in root canal preparation of primary molar teeth. *Int Endod J.* 2013; 46(11):1011-22. DOI: 10.1111/iej.12134

15. Grundy GE, Adkins KF, and Savage NW. Cysts associated with deciduous molars following pulp therapy. *Aust Dent J.* 1984; .29:249-56. DOI: 10.1111/j.1834-7819.1984.tb06067.x

**Fontes de financiamento:** Não

**Conflito de interesse:** Não

**Recebido:** 09/03/2022

**Aprovado:** 17/09/2022

**Publicação:** 04/10/2022

**Endereço para correspondência:** Marcus Victor Vaz Soares Castro. MSc Student, Graduate Program in Dentistry, Federal University of Piauí, Ininga / CEP: 64049-550 Teresina (Piauí), Brazil. (86) 3237-1517/ e-mail: m.vvazod@gmail.com